





## A case series of pulmonary hypertension in small infants with atrial septal defect

Mohammad Reza Sabri<sup>(1)</sup> , Chehreh Mahdavi<sup>(2)</sup> , Hamid Bigdelian<sup>(3)</sup>, Ali Reza Ahmadi<sup>(4)</sup>, Mehdi Ghaderian<sup>(4)</sup>, Bahar Dehghan<sup>(2)</sup>

### Case Series

#### Abstract

**BACKGROUND:** Atrial septal defect (ASD) is one of the most common congenital heart defects (CHDs) with prevalence of 8% to 10% in children with CHD and incidence of 56 per 100000 live births. It is categorized according to the defect site in which the most common form is secundum ASD (ASD<sub>2</sub>) with the defect in the central part of the atrial septum.

**CASE REPORT:** In our case series, we evaluated five children aged under one year old with ASD<sub>2</sub> and pulmonary hypertension (PH). All the patients were referred for surgical ASD closure. Their PH was improved and the size of right atrium (RA) and right ventricle (RV) became normal during the follow-up and one year after the surgery all of them had normal pulmonary artery pressure (PAP) with normal RA and RV size.

**CONCLUSION:** According to our study and those done by others, the prevalence of PH in infants with ASD is low, but when this combination is found without any other CHD, ASD closure should be considered.

**Keywords:** Atrial Septal Defect; Pulmonary Hypertension; Congenital Heart Defects; Infant

*Date of submission:* 10 Feb. 2020, *Date of acceptance:* 12 Apr. 2020

#### Introduction

Atrial septal defect (ASD) is one of the most common congenital heart defects (CHDs). Its prevalence is about 8%-10% of CHDs.<sup>1</sup> It is categorized into four types in which secundum ASD (ASD<sub>2</sub>) is the most common with the defect in the site of fossa ovalis.

Although ASDs are most of the time asymptomatic in infancy, sometimes there might be signs of pulmonary over flow such as poor weight gain and recurrent respiratory infection.<sup>1</sup> Pulmonary hypertension (PH) which is defined as mean pulmonary artery pressure (PAP) above 25 mmHg, is sometimes seen in CHDs which causes significant left to right shunt.<sup>2</sup>

The association of PH and ASD is rarely seen in children<sup>3</sup> and the prevalence of PH in patients with ASD is low unless they are in their thirties to fifties.<sup>1</sup> The prevalence of PH is more in sinus venous type than ASD<sub>2</sub>.<sup>4</sup> The risk of PH in very low birth weight (VLBW) neonates is 4%-16%, specially

when it is associated with ASD.<sup>5</sup> In this report, we present 5 infants with ASD and PH which were treated after surgical correction.

#### Case Report

**Case 1:** The first case was an eight-month-old girl with history of prematurity who was referred to our office because of recurrent respiratory infection. Her weight was 5 kg which was under optimal weight for her age. On auscultation, she had normal first heart sound (S1), loud pulmonic closure sound (P2) with fixed splitting, and right ventricular (RV) heave. Her electrocardiogram (ECG) showed sinus rhythm (NSR) with right axis deviation (RAD)

**How to cite this article:** Sabri MR, Mahdavi C, Bigdelian H, Ahmadi AR, Ghaderian M, Dehghan B. **A case series of pulmonary hypertension in small infants with atrial septal defect.** ARYA Atheroscler 2020; 16(4): 208-10.

1- Professor, Pediatric Cardiovascular Research Center, Cardiovascular Research Institute, Isfahan University of Medical Sciences, Isfahan, Iran

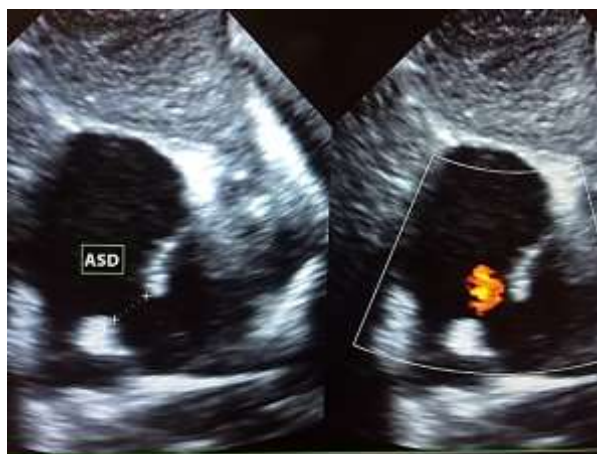2- Assistant Professor, Pediatric Cardiovascular Research Center, Cardiovascular Research Institute, Isfahan University of Medical Sciences, Isfahan, Iran

3- Associate Professor, Interventional Cardiology Research Center, Cardiovascular Research Institute, Isfahan University of Medical Sciences, Isfahan, Iran

4- Associate Professor, Pediatric Cardiovascular Research Center, Cardiovascular Research Institute, Isfahan University of Medical Sciences, Isfahan, Iran

Address for correspondence: Chehreh Mahdavi; Assistant Professor, Pediatric Cardiovascular Research Center, Cardiovascular Research Institute, Isfahan University of Medical Sciences, Isfahan, Iran; Email: chehreh\_m@yahoo.com

and right ventricular hypertrophy (RVH). Echocardiography revealed a moderate to large size ASD<sub>2</sub> (size = 9 mm) with dilated right atrial (RA) and RV (Figure 1), moderate tricuspid regurgitation (TR) with 66 mmHg gradient in favor of PH. Computed tomography (CT) angiography was performed after diagnosis which ruled out any additional CHD. The patient had been on medication while she had surgical closure of the defect about two months after the diagnosis. PH improved after surgical ASD closure, and in one year follow-up, the patient had normal PAP and we discontinued her medication.

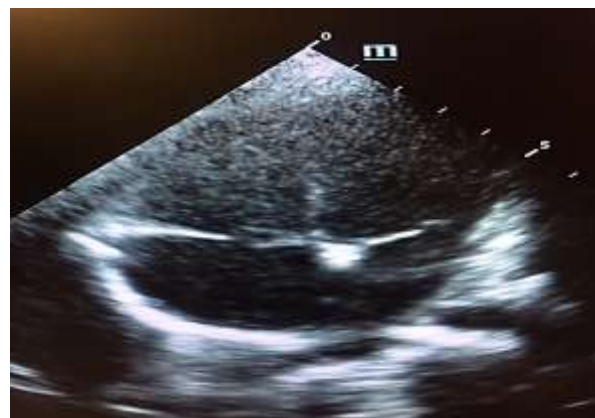

**Figure 1.** Subcostal coronal view of an eight-month-old girl with atrial septal defect (ASD). Note the right atrial (RA) enlargement and secundum ASD (ASD<sub>2</sub>)

**Case 2:** The second case was an eight-month-old girl who was referred due to a heart murmur. She had poor weight gain. Her physical exam showed normal S1 with loud P2 and a systolic murmur grade 2/6 on left sternal border (LSB) with RV heave but no thrill. On ECG, there was NSR, rsR' pattern in V1 and V2, and RVH. Echocardiography showed moderate to large ASD<sub>2</sub> (size = 8 mm) with RA and RV enlargement and moderate TR with 87 mmHg gradient. CT angiography was performed one month after diagnosis which showed mild aortic arch hypoplasia (AAH) and large ASD<sub>2</sub> (size = 12 mm). Medication was started soon after diagnosis and the patient had surgical closure in about two months after diagnosis. About eight months after the surgery, PAP and RA and RV sizes were normal and no more drugs were needed.

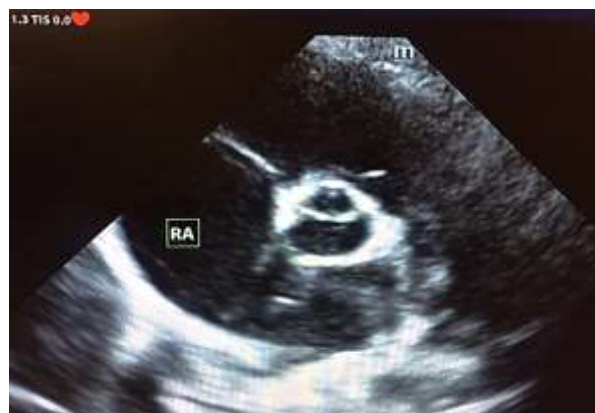**Case 3:** The third case was a six-month-old girl who was referred due to failure to thrive (FTT). She had normal S1, loud P2, and RV heave on physical exam. ECG showed NSR, RAD, and strain pattern in right precordial leads. In echocardiography, there was RA and RV enlargement with moderate to large

ASD<sub>2</sub> (size = 10 mm) and moderate TR with 120 mmHg gradient (Figure 2). CT angiography after diagnosis ruled out any other CHD. Surgical closure was done two months after diagnosis and cease of medication and normal PAP were achieved in about three months after operation.



**Figure 2.** Apical four-chamber view of a six-month-old girl with moderate to large secundum atrial septal defect (ASD<sub>2</sub>) and right atrial (RA) and right ventricular (RV) enlargement

**Case 4:** The fourth case was a five-month-old girl who was referred to our clinic due to FTT and poor weight gain. On the physical exam, she had normal S1, with fixed splitting of S2, and a systolic murmur with grade 2/6 on LSB. On ECG, she had NSR, RAD, and pure R wave in V1 in favor of RVH and in echocardiography, dilatation of RA and RV was prominent with moderate TR with 50 mmHg gradient and a large ASD<sub>2</sub> (size = 14 mm) and PH (Figure 3). She was referred to surgeon for operation which was done two weeks after the diagnosis. Postoperative echocardiography revealed mild TR and improving PH.



**Figure 3.** Parasternal short axis (PSAX) view of a four-month-old girl. Note the right atrial (RA) enlargement and large secundum atrial septal defect (ASD<sub>2</sub>)

**Case 5:** Our fifth case was a 7.5-month-old girl with recurrent pneumonia who had a systolic murmur in LSB and RV heave in physical exam. She had NSR, RAD, and RVH in ECG and a large ASD<sub>2</sub> (size = 12 mm) with dilated RA and RV, moderate TR with gradient of 87 mmHg, and PH on echocardiography. For further evaluation, CT angiography was done which ruled out any additional CHD. Medical therapy was started. The patient was referred to surgeon and ASD closure was done about 1.5 months after the diagnosis. Postoperative echo showed improved PH and mild TR.

**Ethical Approval:** All procedures performed in studies involving human participants were in accordance with the ethical standards of the institutional and/or national research committee and with the 1964 Helsinki Declaration and its later amendments or comparable ethical standards.

Informed consent was obtained from the parents of infants involved in our study.

### Discussion

ASD is one of the most common CHDs with incidence of 56 per 100000 live births. Its survival rate is about 97%.<sup>6</sup> Although it is mostly sporadic, there are reports of familial ASDs and also it is seen in Holt-Oram syndrome (HOS), Noonan syndrome (NS), and Down syndrome (DS). It is usually asymptomatic in infancy and early childhood; however, it might present with signs of pulmonary overflow such as low weight gain and recurrent respiratory infection. Occurrence of PH in patients with ASD is rare in infants and small children and mostly is seen in adulthood.<sup>3</sup> Association of ASD with PH is reported to be more prevalent in sinus venous type than ADS<sub>2</sub>.<sup>4</sup> Sometimes there is an unapparent PH with ASD which is manifested during exercise stress echo, in which ASD closure helps in reducing PH.<sup>7</sup> PH is defined as mean PAP of more than 25 mmHg and systolic PAP (sPAP) of more than 35 mmHg. There are some predictors for PH in patients with ASD such as age, female sex, size of defect, and non-closed status.<sup>6</sup>

To evaluate PAP, there are different modalities such as echocardiography in which TR and PI pressure gradients are of use as well as right heart catheterization which is a more reliable technique. Vyas-Read et al. in a research on premature infants with PH found that those with ASD were at higher risk for developing PH.<sup>5</sup> Goetschmann et al. in another study about the association of ASD and PH in children concluded that although this combination was rarely seen, it might happen in children and closure of the defect would help in improving PH.<sup>3</sup>

Despite the low probability of PH in children with ASD, there are few cases of ASD and PH without any other CHD in which evaluation of the predisposing factors and risks of PH and ruling out primary PH (PPH) is recommended and if nothing is found, it is beneficial to close ASD to improve PH.

According to our study and those done by others, the prevalence of PH in infants with ASD is low, but when this combination is found without any other CHD, ASD closure should be considered. By decreasing pulmonary blood flow by ASD closure, we can effectively improve PH.

### Acknowledgments

The authors appreciate all the people who helped in performing this study.

### Conflict of Interests

Authors have no conflict of interests.

### References

1. Sachdeva R. Atrial septal defects in Hugh. In: Allen HD, Shaddy RE, Penny DJ, Feltes TF, Cetta F, Editors. Moss & Adams' heart disease in infants, children, and adolescents, including the fetus and young adult. Philadelphia, PA: Wolters Kluwer; 2016. p. 739-43.
2. Dunbar I. Pediatric pulmonary hypertension. In: Allen HD, Shaddy RE, Penny DJ, Feltes TF, Cetta F, Editors. Moss & Adams' heart disease in infants, children, and adolescents, including the fetus and young adult. Philadelphia, PA: Wolters Kluwer; 2016. p. 1519.
3. Goetschmann S, Dibernardo S, Steinmann H, Pavlovic M, Sekarski N, Pfammatter JP. Frequency of severe pulmonary hypertension complicating "isolated" atrial septal defect in infancy. *Am J Cardiol* 2008; 102(3): 340-2.
4. Vogel M, Berger F, Kramer A, Alexi-Meshkishvili V, Lange PE. Incidence of secondary pulmonary hypertension in adults with atrial septal or sinus venosus defects. *Heart* 1999; 82(1): 30-3.
5. Vyas-Read S, Guglani L, Shankar P, Travers C, Kanaan U. Atrial septal defects accelerate pulmonary hypertension diagnoses in premature infants. *Front Pediatr* 2018; 6: 342.
6. Post MC. Association between pulmonary hypertension and an atrial septal defect. *Neth Heart J* 2013; 21(7-8): 331-2.
7. Lange SA, Braun MU, Schoen SP, Strasser RH. Latent pulmonary hypertension in atrial septal defect: Dynamic stress echocardiography reveals unapparent pulmonary hypertension and confirms rapid normalisation after ASD closure. *Neth Heart J* 2013; 21(7-8): 333-43.